

Urethral stricture disease in men

STELLA L. IVAZ, SIMON BUGEJA AND DANIELA E. ANDRICH

Most urethral strictures are either idiopathic or iatrogenic secondary to urethral instrumentation or failed surgery for hypospadias. In this article, the authors provide a concise general overview of urethral stricture and its management.

Urethral stricture disease is common, with a reported prevalence of 10 per 100 000 men in their youth, 20 per 100 000 by the age of 55, rising up to 100 per 100 000 in men over the age of 65 years.¹

A urethral stricture is defined as a scar of the subepithelial tissue of the corpus spongiosum, which constricts the urethral lumen.² This may result in a variety of obstructive lower urinary tract symptoms and, if left untreated, may lead to complications from high pressure voiding; a thick-walled trabeculated bladder, urinary tract infections (including prostatitis and epididymo-orchitis) and renal impairment may ensue.

This article relates to strictures of the anterior urethra. This is the part that

VIDEO

Go to the *Trends* website to view a short video by Tony Mundy on urethral stricture disease in men www.trendsinnmenshealth.com/video

runs from the perineal membrane to the external urethral meatus and is surrounded by the corpus spongiosum.

AETIOLOGY

Historically, strictures were associated with urethritis and trauma.³ Nowadays, in the western world, most strictures are either idiopathic or iatrogenic secondary to urethral instrumentation or failed surgery for hypospadias. Idiopathic strictures are those of unknown aetiology and those occurring in young adults at the junction of the proximal and middle thirds of the bulbar urethra, which some authorities believe are congenital.^{4,5}

Aetiology is related to the patient's age and the stricture location. The commonest site for a stricture is the bulbar urethra, which is the part enveloped by the bulbospongiosus muscle. Bulbar strictures are commonly idiopathic or the result of iatrogenic trauma. Penile strictures, on the other hand, are most commonly hypospadias-related or secondary to lichen sclerosus (LS), formerly known as balanitis xerotica obliterans. Classically, LS starts at the meatus and may spread proximally to involve the entire length of the penile and bulbar urethra.⁶

EVALUATION

Patients often present with progressively worsening lower urinary tract symptoms. These include a poor and prolonged

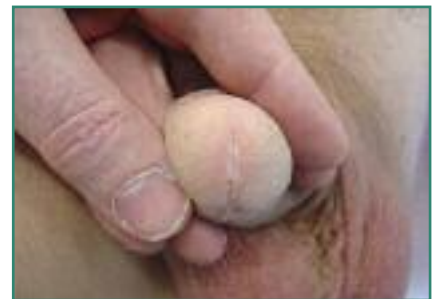

Figure 1. Mild lichen sclerosus: a small white area can be seen around the meatus

stream, hesitancy, terminal dribbling and incomplete emptying. Less common presentations include pain, acute or chronic retention, urinary tract infections and/or haematuria.

The penis should be examined for evidence of LS. Signs of this can be subtle, with a small white area seen around the meatus (Figure 1), or may be more extensive, leading to severe scarring and deformity (Figure 2). The calibre of the meatus should be assessed. Urethral strictures are rarely palpable, except sometimes in LS and after infection or trauma.

A flow rate and post-void residual volume of urine are useful in the assessment of men with suspected urethral stricture disease. A prolonged flow pattern with a plateau appearance is characteristic. Additionally, symptom scores such as the American Urological Association symptom index⁷ or the

Stella L. Ivaz, MB BS, BMus(Hons), MA, MRCS, FRCS(Urol), Specialty Trainee in Reconstructive Urology; Simon Bugeja, MD, MSc, MRCS, FEBU, Fellow in Reconstructive Urology; Daniela E. Andrich, MD, MSc, FRCS(Urol), Consultant in Reconstructive Urology, University College London Hospital

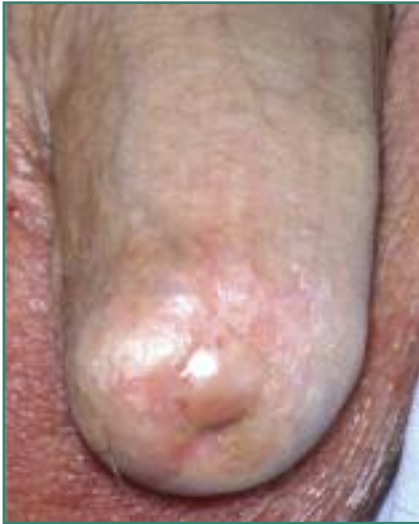

Figure 2. Severe lichen sclerosus

urethral stricture surgery patient-reported outcome measure⁸ may be given to patients to define symptomatology.

Ultrasound evaluation of the upper urinary tract is indicated if chronic bladder outflow obstruction is suspected. An ascending/descending urethrogram provides valuable information regarding the length and location of the stricture (Figures 3 and 4). This is particularly useful when planning surgical reconstruction. When a urethrogram is inconclusive, direct endoscopic visualisation of the stricture may be indicated.

MANAGEMENT OF URETHRAL STRICTURE

No two strictures are the same, even if they occur within the same segment of the urethra. In addition to location, stricture aetiology, length, severity of spongiofibrosis and previous surgical intervention will all influence the management strategy. Patient factors such as symptom severity, impact on overall quality of life, erectile function, comorbidities, and the ideas, concerns and expectations of the man himself play a vital role in the shared decision-making process.

The therapeutic options for urethral stricture disease are diverse, ranging from minimally invasive techniques such as urethral dilatation and direct-vision internal

urethrotomy (DVIU), to anastomotic and augmentation/substitution urethral reconstruction, and perineal urethrostomy.⁹

If a man's symptoms are not particularly troublesome, a conservative approach to management is entirely reasonable in the absence of complications such as impaired renal function.

Endoscopic intervention

The simplest forms of intervention are urethral dilatation (where the stricture is circumferentially stretched) and DVIU (where the fibrosis is incised) in the hope that healing by secondary intention will occur before further scarring.

The cure rate is only around 50%, if that, and this applies only to short strictures of the bulbar urethra.¹⁰ The long-term success rate and cost-effectiveness decrease even further with subsequent attempts at endoscopic intervention.¹¹ There is nonetheless still an important role for regular endoscopic intervention in patients who are not keen on surgical reconstruction; those in whom this is required only infrequently; those who are unfit for general anaesthesia; or those who have failed multiple previous surgical interventions but who wish to preserve urethral voiding.

An alternative to endoscopic intervention in a hospital setting for some patients is self-dilatation by the patient using a catheter – so-called clean intermittent self-catheterisation.

Urethroplasty

Urethroplasty remains the only curative treatment option for many men with urethral stricture disease. The type of urethroplasty depends on the location and length of the stricture, its aetiology and the severity of the spongiofibrosis. It is essential to take into account any previous surgery when making decisions about reconstructive options, because this may have a bearing on the availability of tissue (skin or oral mucosa) for urethral augmentation or substitution.

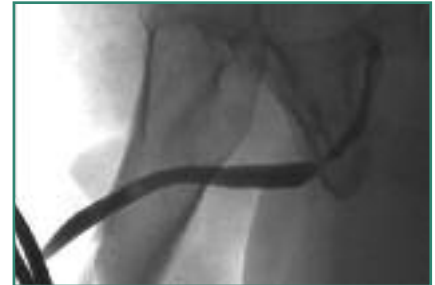

Figure 3. Urethrogram showing short idiopathic bulbar urethral stricture

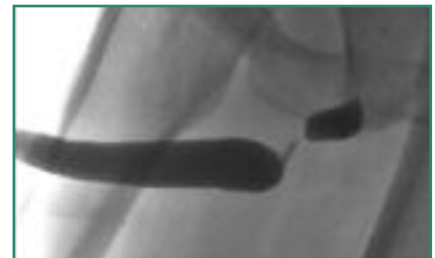


Figure 4. Urethrogram showing long bulbar urethral stricture: typical appearance for fall-astride urethral injury

A man's first urethroplasty has the highest chance of being successful and the best results from urethroplasty are achieved in specialist, high-volume centres, hence the importance of early referral to a specialist unit.

Bulbar urethroplasty

This is the most common type of urethroplasty, performed with success rates in excess of 90%.

For short bulbar strictures (2–3cm in length), the traditional gold-standard procedure has been stricture excision and end-to-end anastomosis. This, however, involves transection of the corpus spongiosum with potential negative consequences on the blood supply to the urethra. In most idiopathic bulbar strictures the spongiofibrosis is only superficial, with healthy residual underlying spongiosum, so there is now a trend towards non-transection for short idiopathic bulbar strictures.¹²

In the non-transecting anastomotic bulbar urethroplasty, only the spongiofibrosis is excised with a tension-free mucosa-to-mucosa anastomosis preserving the

integrity of the spongiosal blood flow. Transection and anastomosis is increasingly being performed only in post-traumatic bulbar strictures with full-thickness spongiofibrosis.

End-to-end anastomosis is not possible in longer strictures because of the tension it puts on the anastomosis (which increases the risk of stricture recurrence) and the potential for penile curvature. In these cases augmentation urethroplasty is the best approach, where the stricture is divided longitudinally (stricturotomy) either dorsally or ventrally and augmented using a graft. That graft is most commonly buccal mucosa harvested from the inside of the cheek or sublingual area.¹³

Penile urethroplasty

In the penile urethra, excision and end-to-end anastomosis is not an option because of buckling and curvature of the penis. Therefore the two options here are a stricturotomy and patch or excision, with circumferential reconstruction in cases of severe fibrosis. Skin flaps were used historically; however, they are associated with complications such as hair growth, stone formation, haematoma and graft shrinkage. For these reasons they have gone out of favour and oral mucosa is now the substitution material of choice. Skin flaps should *never* be used in LS-related strictures because of the tendency for this condition to recur in skin exposed to urine.

When circumferential reconstruction is required (for example when excising a scarred 'old' hypospadias skin flap), a staged procedure using an oral graft may be necessary, because one-stage tube grafts do not 'take' well and have a very high recurrent stricture rate.¹³ The staged approach usually involves two subsequent operations 4–6 months apart. At the first stage buccal mucosa (usually) is grafted on to the ventral aspect of the shaft of the penis. This almost always 'takes' well. At the second stage this flat strip of graft is rolled up into a tube to create the new urethra.

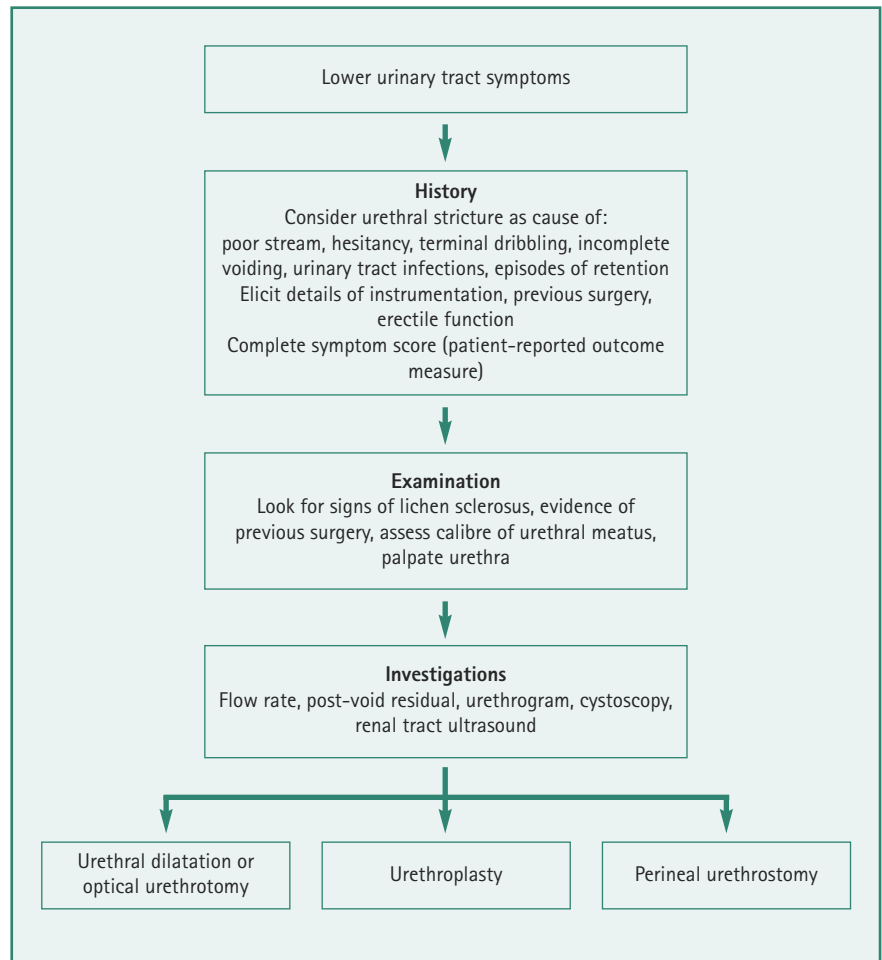


Figure 5. Steps in the initial assessment of patients with urethral stricture disease

In other penile stricture aetiologies, such as LS, or catheter-related penile strictures, we are keen to preserve the remaining healthy spongiosal tissue of the urethra and rather augment the urethra to normal calibre by using a dorsal strip of oral mucosal graft, all of which is usually achieved in one operation.

Penile urethral reconstruction is highly subspecialised and not 'forgiving' surgery. Patients need to be aware that there is a higher risk of failure in penile urethral reconstruction compared to bulbar urethroplasty techniques. If there was a problem with graft healing, further grafting may be necessary, so that a planned 'two-stage procedure' can add up to requiring three or more operations, which quickly can become a problem as there is a finite supply of oral

mucosa! The only significant factor that reduces the risk of complications in penile urethral reconstruction is the expertise of the surgeon.

In the most extreme cases, salvage penile urethroplasty is not feasible and the only option remaining is a permanent perineal urethrostomy.

Perineal urethrostomy

Perineal urethrostomy involves the creation of a new urethral opening onto the skin in the perineum at the level of the mid-bulbar urethra, thus 'bypassing' the rest of the anterior urethra. Patients need to sit down to void and they should be made aware that ejaculation will occur through the new

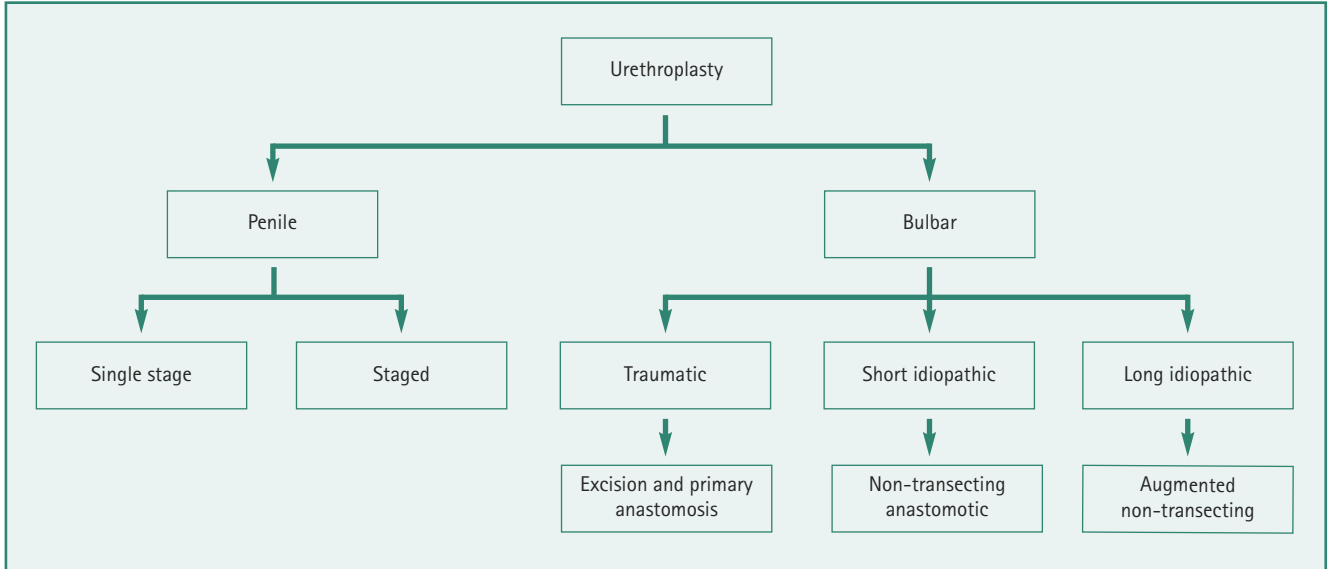


Figure 6. Reconstructive urethroplasty techniques

urethral opening in the perineum. A perineal urethrostomy does not, however, interfere with urinary continence, as the external urethral sphincter remains intact. This procedure is still a very useful therapeutic option for men who have extensive urethral stricture disease and where multiple reconstructive procedures have failed, and for those who do not wish to undergo (or are not medically fit for) yet another attempt at urethral reconstruction.¹⁴

KEY POINTS

- Urethral stricture disease is more common than people think. Consider it as a cause of progressive lower urinary tract symptoms in men
- Patient factors and urethral stricture characteristics are equally important in the shared decision-making process that guides the management of this complex health problem
- Urethral reconstruction should be performed in specialist, high-volume centres

SUMMARY

The steps involved in the initial assessment of men with urethral stricture disease are summarised in Figure 5; reconstructive urethroplasty techniques are summarised in Figure 6.

Declaration of interests: none declared.

REFERENCES

1. McMillan A, Pakianathan M, Mao JH, et al. Urethral stricture and urethritis in men in Scotland. *Genitourin Med* 1994; 70:403–5.
2. Mundy AR, Andrich DE. Urethral strictures. *BJU Int* 2011;107:6–26.
3. Beard DE, Goodyear WE. Urethral stricture; a pathological study. *J Urol* 1948;59:619–26.
4. Netto NR Jr, Martucci RC, Goncalves ES, et al. Congenital stricture of male urethra. *Int Urol Nephrol* 1976;8:55–61.
5. Donnellan SM, Costello AJ. Congenital bulbar urethral strictures occurring in three brothers. *Aust NZ J Surg* 1996;66:423–4.
6. Andrich DE, Mundy AR. What's new in urethroplasty? *Curr Opin Urol* 2011;21:455–60.
7. Barry MJ, Fowler FJ Jr, O'Leary MP, et al. Correlation of the American Urological Association symptom index with self-administered versions of the Madsen-Iversen, Boyarsky and Maine

Medical Assessment Program symptom indexes. Measurement Committee of the American Urological Association. *J Urol* 1992;148:1558–64.

8. Jackson MJ, Sciberras J, Mangera A, et al. Defining a patient-reported outcome measure for urethral stricture surgery. *Eur Urol* 2011;60:60–8.
9. Chapple C, Andrich D, Atala A, et al. SIU/ICUD consultation on urethral strictures: the management of anterior urethral stricture disease using substitution urethroplasty. *Urology* 2014;83(3 Suppl):S31–47.
10. Steenkamp JW, Heyns CF, de Kock ML. Internal urethrotomy versus dilation as treatment for male urethral strictures: a prospective, randomized comparison. *J Urol* 1997;157:98–101.
11. Greenwell TJ, Castle C, Andrich DE, et al. Repeat urethrotomy and dilation for the treatment of urethral stricture are neither clinically effective nor cost-effective. *J Urol* 2004;172:275–7.
12. Andrich DE, Mundy AR. Non-transecting anastomotic bulbar urethroplasty: a preliminary report. *BJU Int* 2012;109:1090–4.
13. Andrich DE, Mundy AR. What is the best technique for urethroplasty? *Eur Urol* 2008;54:1031–41.
14. Myers JB, McAninch JW. Perineal urethrostomy. *BJU Int* 2011;107:856–65.